



Clinical Course of Optical Coherence Tomography-Detected Lipid-Rich Coronary Plaque After Optimal Medical Therapy

Junichi Sugiura, MD; Tsunenari Soeda, MD, PhD; Atsushi Kyodo, MD;
Takuya Nakamura, MD; Akihiko Okamura, MD; Kazutaka Nogi, MD;
Yukihiro Hashimoto, MD; Tomoya Ueda, MD, PhD;
Makoto Watanabe, MD, PhD; Yoshihiko Saito, MD, PhD

Background: The aim of this study was to evaluate optical coherence tomography (OCT)-detected lipid-rich coronary plaques (LRCPs) with coronary computed tomography angiography (CCTA) 10 months after optimal medical therapy (OMT).

Methods and Results: Baseline OCT detected 28 LRCPs in non-culprit lesions. High-risk plaque features (HRPFs), such as positive remodeling, very low attenuation plaques, napkin-ring sign, and spotty calcification, were observed in 67.9%, 67.9%, 21.4%, and 64.3% of LRCPs, respectively, at the 10-month follow-up CCTA. Lesions with ≥ 3 HRPFs were defined as high-risk LRCPs ($n=12$); the remaining were defined as low-risk LRCPs ($n=16$). The maximum lipid arc on baseline OCT was larger in high- than low-risk LRCPs ($221\pm 62^\circ$ vs. $179\pm 44^\circ$, respectively; $P=0.04$). Receiver operating characteristic curve analysis indicated that a maximum lipid arc $>154^\circ$ on baseline OCT was the optimal cut-off value to predict high-risk LRCPs 10 months after OMT. Patients with high-risk LRCPs had worse clinical outcomes, defined as a composite of cardiac death, target lesion-related myocardial infarction, and target lesion-related revascularization, during follow-up than those with low-risk LRCPs (33.3% vs. 0%; $P=0.01$).

Conclusions: A high-risk LRCP at follow-up CCTA was correlated with a larger maximum lipid arc on baseline OCT. Further aggressive treatment for patients with large LRCPs may reduce vulnerable plaque features and prevent future cardiac events.

Key Words: Coronary computed tomography; High-risk plaque feature; Lipid rich coronary plaque; Optical coherence tomography; Optimal medical therapy

Recent studies have shown the efficacy of optimal medical therapy (OMT) in patients with advanced coronary artery disease.^{1,2} Several guidelines and clinical trials have emphasized the importance of secondary prevention, especially with lipid-lowering therapy.^{3–6} Despite aggressive OMT, cardiovascular events were documented in 10–20% of cases with advanced coronary artery disease.^{6–8}

Studies using intravascular ultrasound (IVUS) and optical coherence tomography (OCT) demonstrated that lipid-rich coronary plaques (LRCPs) and thin-cap fibroatheromas (TCFA) were precursors of future cardiovascular events, including cardiac death, acute coronary syndrome (ACS), or unplanned percutaneous coronary intervention (PCI).^{9–13} An OCT study showed that the presence of TCFA and microchannels at non-culprit lesions was correlated with the subsequent progression of coronary atheromatous plaques.¹⁴ The incidence of future cardiovascular events is twice as high at lesions with non-culprit LRCPs than at

those without.¹² Therefore, it is important to detect high-risk LRCPs that remain unstable after OMT at non-culprit lesions.

Coronary computed tomography angiography (CCTA) is a useful non-invasive tool for the detection of vulnerable plaques. Several studies have demonstrated a relationship between cardiovascular events and plaque features detected on CCTA.^{15–19} Positive remodeling (PR), low attenuation plaques (LAP), napkin-ring sign (NRS), and spotty calcification were recognized as high-risk plaque features (HRPFs), which are independent predictors of adverse cardiac events.^{15,17} The non-invasive assessment of LRCP after OMT by CCTA is thought to be useful in preventing future coronary events. However, it is unknown which patients with LRCP should undergo CCTA follow-up after OMT.

The aims of this study were to explore the relationship between LRCP on baseline OCT and HRPFs on CCTA 10 months after OMT and to identify high-risk LRCPs.

Received November 9, 2021; accepted November 9, 2021; J-STAGE Advance Publication released online December 3, 2021 Time for primary review: 1 day

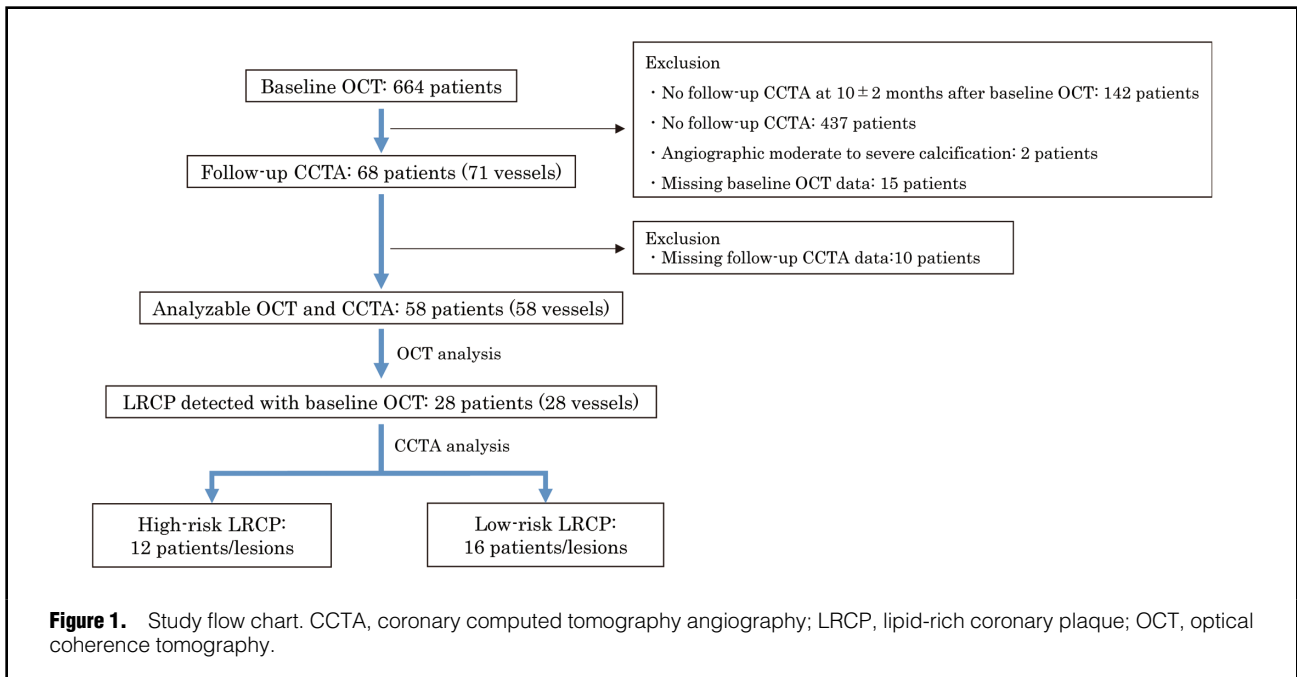
Cardiovascular Medicine, Nara Medical University, Kashihara, Japan

Mailing address: Tsunenari Soeda, MD, PhD, Cardiovascular Medicine, Nara Medical University, 840 Shijo-cho, Kashihara 634-8521, Japan. E-mail: tsunenari0414@hotmail.com

All rights are reserved to the Japanese Circulation Society. For permissions, please e-mail: cr@j-circ.or.jp

ISSN-2434-0790





Methods

Study Population

Patients with LRCP on baseline OCT who underwent CCTA a mean of 10 ± 2 months after baseline OCT at Nara Medical University between February 2012 and January 2021 were enrolled in the study. Of the 664 patients who were screened, 58 ($n=58$ vessels) were found to have with analyzable CCTA at the 10 ± 2 -month follow-up. Of these, 28 patients ($n=28$ vessels) with LRCP detected by baseline OCT were included in the present study (Figure 1). Patient characteristics were collected from medical records. Blood test results were collected within 3 months of baseline OCT or follow-up CCTA.

The study protocol was approved by the Ethics Committee of Nara Medical University (ID #1759-2) and the study was performed in accordance with the 1975 Declaration of Helsinki guidelines for clinical research protocols. All patients provided informed consent.

OCT Study and Analysis

OCT was performed at the operator's discretion for PCI guidance or for follow-up of a previously implanted stent with a frequency-domain OCT system (Illumien C7-XR, Illumien Dragonfly OPTIS, or Illumien Dragonfly OPSTAR [Abbott Vascular, Santa Clara, CA, USA] or LUNAWAVE [Terumo, Tokyo, Japan]). The OCT imaging technique has been described previously.²⁰

OCT was performed at the non-culprit lesion including the LRCP and at each lesion between 2 normal regions or between the normal region and a region 5 mm from the implanted stent. The "normal region" was defined as a lesion with a lipid arc $< 90^\circ$. In-stent lesions were excluded. LRCP was defined as a signal-poor region with diffuse borders, a lipid arc $\geq 90^\circ$,²⁰ and a fibrous cap thickness $< 200 \mu\text{m}$ based on a previous study that reported that few plaque ruptures occurred in lesions with fibrous caps thicker than $200 \mu\text{m}$.²¹ For each lesion, we evaluated the

maximum lipid arc (measured on the cross-sectional image with the largest amount of lipid), lipid length (mm; calculated by the number of cross-section images with lipid pool), the lipid index (defined as the sum of the lipid arc in each 1-mm cross-section), minimum fibrous cap thickness (μm ; measured at the thinnest part of the LRCP), and the presence of TCFA, macrophages, microchannels, cholesterol crystals, calcification, thrombus, and layered plaque (defined as plaques with ≥ 1 layers of different optical density and a clear demarcation from underlying components).^{20,21} Cross-section analyses were performed at 1-mm intervals.

OCT images were analyzed using offline software at Nara Medical University by 2 investigators (A.K. and T.N.) familiar with OCT analysis. Disagreements on analysis were settled by a consensus reading from a third independent investigator (A.O.).

CCTA Procedure and Analysis

The CCTA was performed using a dual-source CT scanner (Somatom Definition; Siemens, Forchheim, Germany). The detailed scan protocol is described in the **Supplementary Methods**.

CCTA analysis was performed using SYNAPSE VINCENT version 5.1. Images were independently evaluated by 3 investigators (J.S., T.S. and K.N.) familiar with CCTA analysis; disagreements were settled by consensus. CCTA studies were performed for each lesion detected by baseline OCT. The lesion was analyzed from the proximal normal region (plaque thickness $< 600 \mu\text{m}$) to the distal region, except for in-stent lesions and lesions within 5 mm of the implanted stent. Coronary plaques were defined as structures with a minimum area of 1 mm^2 within or adjacent to the arterial lumen, clearly distinguishable from the vessel lumen, and surrounded by pericardial tissue; tissue with a signal intensity below -30 Hounsfield units (HU) was considered pericardial fat and was excluded from the analysis. Each tissue was classified by its CT value: less than -30 HU, pericardial fat; between -30 and 50 HU,

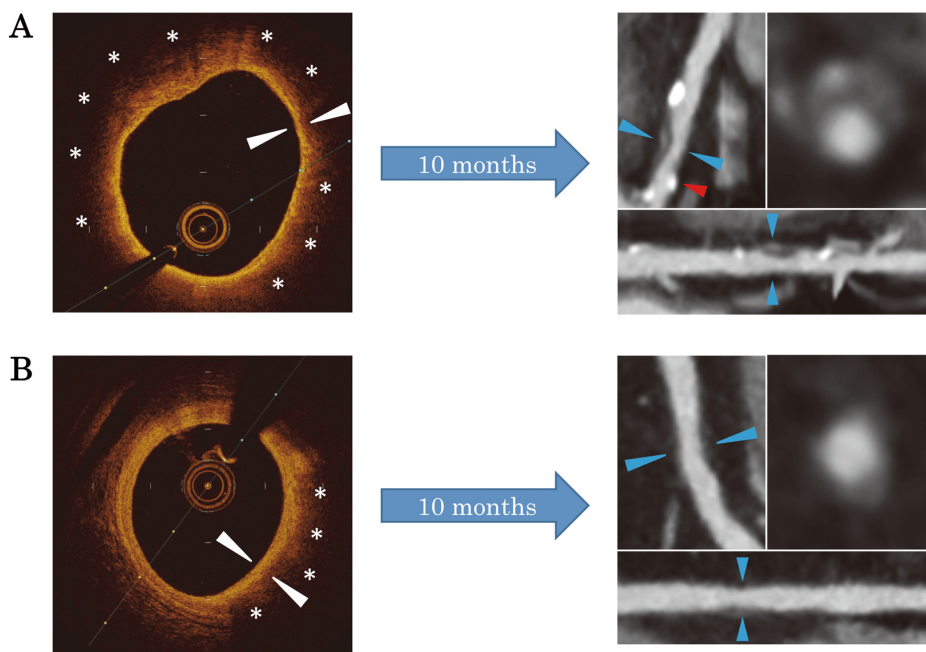


Figure 2. Representative images of baseline optical coherence tomography (OCT) and follow-up coronary computed tomography angiography (CCTA) findings. **(A)** Representative image of lipid-rich coronary plaque (LRCP) showing high-risk LRCP at follow-up. The OCT image shows a large lipid core with a thin fibrous cap. The maximum lipid arc is 320° (asterisks) and the minimum fibrous cap thickness was 50 μm (white arrowheads). The CCTA image of the same lesion shows high-risk plaque features (HRPFs) with positive remodeling (remodeling index 1.2), very low attenuation plaque (minimum CT value -2 HU), napkin-ring sign (blue arrowheads), and spotty calcification (red arrowhead). **(B)** Representative image showing low-risk LRCP at follow-up. The OCT image shows a maximum lipid arc of 100° (asterisks) and a minimum fibrous cap thickness of 120 μm. The CCTA image at follow-up showed no HRPF (remodeling index 1.04 and minimum CT value 45 HU).

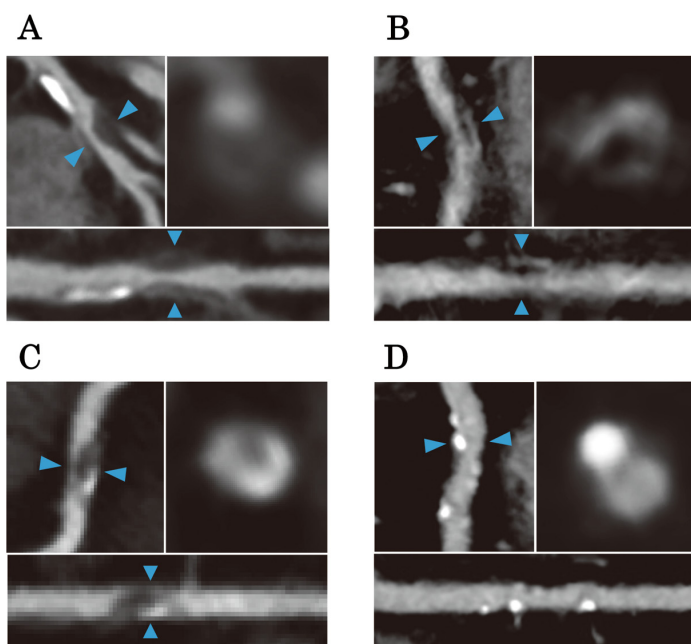


Figure 3. Representative images of each high-risk plaque feature (HRPF) on computed tomography angiography (CCTA). **(A)** Positive remodeling (blue arrowheads). The remodeling index was 1.26. **(B)** Very low attenuation plaque (blue arrowheads). The minimum CT value within the low-attenuation area was -10 HU. **(C)** Napkin-ring sign (blue arrowheads). **(D)** Spotty calcification (blue arrowheads). Left upper panels show curved multiplanar reconstruction images, whereas right upper panels show cross-section images of the areas indicated by the blue arrowheads. Lower panels show straight multiplanar reconstruction images.

Table 1. Clinical Characteristics, Medication at Discharge and Laboratory Findings in Patients With Low- and High-Risk LRCs				
	All patients (n=28)	High-risk LRCs (n=12)	Low-risk LRCs (n=16)	P value
Age (years)	68±12	67±9	69±14	0.67
Male sex	22 (78.6)	11 (91.7)	11 (68.8)	0.14
BMI (kg/m²)	24.0±3.8	24.0±4.3	24.1±3.4	0.94
Hypertension	20 (71.4)	10 (83.3)	10 (62.5)	0.23
Dyslipidemia	26 (92.9)	11 (91.7)	15 (93.8)	0.83
Diabetes	7 (25)	2 (16.7)	5 (31.3)	0.38
CKD	6 (21.4)	2 (16.7)	4 (25.0)	0.59
Hemodialysis	1 (3.6)	0 (0)	1 (6.3)	0.38
Prior MI	19 (67.9)	10 (83.3)	9 (56.3)	0.13
Brinkman index	550 [0–1,198]	500 [0–1,500]	550 [13–1,050]	0.89
Family history of coronary artery disease	6 (21.4)	3 (25.0)	3 (18.8)	0.69
Medications at discharge				
Aspirin	25 (89.3)	10 (83.3)	15 (93.8)	0.38
Thienopyridine	27 (96.4)	12 (100)	15 (93.8)	0.28
Oral anticoagulant	5 (17.9)	3 (25.0)	2 (12.5)	0.39
β-blocker	23 (82.1)	11 (91.7)	12 (75.0)	0.25
RAS blocker	22 (78.6)	11 (91.7)	11 (68.8)	0.14
Statin	27 (96.4)	12 (100)	15 (93.8)	0.38
Ezetimibe	12 (42.9)	5 (41.7)	7 (43.8)	0.91
Evolocumab	1 (3.6)	0 (0)	1 (6.3)	0.38
Fibrate	0 (0)	0 (0)	0 (0)	–
EPA/DHA	2 (7.1)	1 (8.3)	1 (6.3)	0.83
Oral hypoglycemic agents	4 (1.4)	2 (16.7)	2 (12.5)	0.76
Insulin	2 (7.1)	1 (8.3)	1 (6.3)	0.83
Laboratory findings				
LDL-C (mg/dL)				
At baseline	106±46	93±35	115±51	0.22
At follow-up	65±20	67±22	63±20	0.63
HDL-C (mg/dL)				
At baseline	50±10	47±8	52±11	0.21
At follow-up	53±9	51±9	54±9	0.37
Triglyceride (mg/dL)				
At baseline	132 [71–179]	132 [85–178]	130 [65–202]	0.76
At follow-up	122 [87–185]	146 [94–193]	122 [85–183]	0.45
HbA1c (%)				
At baseline	6.2±0.8	6.0±0.6	6.3±1.0	0.48
At follow-up	6.5±0.6	6.4±0.6	6.5±0.6	0.81
Creatinine at baseline (mg/dL)	0.82 [0.73–0.96]	0.82 [0.73–0.99]	0.82 [0.71–0.93]	0.43
eGFR at baseline (mL/min/1.73m ²)	67.3±17.5	67.9±12.2	66.8±21.0	0.87

Unless indicated otherwise, data are given as n (%), mean±SD, or the median (interquartile range). BMI, body mass index; CKD, chronic kidney disease; DHA, docosahexaenoic acid; eGFR, estimated glomerular filtration rate; EPA, eicosapentaenoic acid; HDL-C, high-density lipoprotein cholesterol; LDL-C, low-density lipoprotein cholesterol; LRCs, lipid-rich coronary plaque; MI, myocardial infarction; RAS, renin-angiotensin system.

LAP; 51–200 HU, fibrous plaque; 201–500 HU, enhanced media; 501 HU, calcification.^{15,22}

Previous studies showed that HRPFs in lesions, such as PR, very (v) LPAs, NRS, and spotty calcifications, are predictive of cardiac events.^{15,17} In the present study, PR was defined as a lesion with a remodeling index ≥1.1, vLAP was defined as a minimum CT value ≤30 HU, NRS was defined as a central low-attenuation portion surrounded by ring-like higher attenuation, and spotty calcification was defined as small calcification that had ≤3-mm calcification on curved multiplanar reformation images and occupied only 1 side on cross-sectional images. Baseline OCT findings

and patient characteristics were compared for each HRPF.

In a previous report, lesions with ≥3 HRPFs were significantly associated with low fractional flow reserve and target vessel events.²³ Therefore, in the present study we calculated the total number of each HRPFs for all lesions, and high-risk LRCs were defined as lesions with ≥3 HRPFs, whereas low-risk LRCs were defined as lesions with <3 HRPFs. Patients with high-risk LRCs were compared to those with low-risk LRCs. Other morphological plaque features were assessed, as described in the **Supplementary Methods**. Representative images of LRCs and each HRPF are shown in **Figures 2 and 3**.

	High-risk LRCP (n=12)	Low-risk LRCP (n=16)	P value
Maximum lipid arc (°)	221±62	179±44	0.04
Lipid length (mm)	5.3 [3.4–8.5]	6.4 [4.9–9.9]	0.34
Lipid index	1,033 [679–1,481]	971 [817–1,622]	0.96
Minimum FCT (μm)	62 [47–79]	64 [50–122]	0.58
TCFA	6 (50.0)	8 (50.0)	1.00
Macrophages	11 (91.7)	13 (81.3)	0.44
Microchannels	4 (33.3)	9 (56.3)	0.23
Cholesterol crystals	2 (16.7)	6 (37.5)	0.23
Calcification	9 (75.0)	11 (68.8)	0.72
Thrombus	2 (16.7)	0 (0)	0.09
Layered plaque	6 (50.0)	5 (31.3)	0.31
Lesion			0.58
RCA	5 (41.7)	3 (18.8)	
LMT	1 (8.3)	2 (12.5)	
LAD	5 (41.7)	10 (62.5)	
LCX	1 (8.3)	1 (6.3)	

Unless indicated otherwise, data are given as n (%), mean±SD, or median (interquartile range). FCT, fibrous cap thickness; LAD, left anterior descending; LCX, left circumflex artery; LMT, left main trunk; LRCP, lipid-rich coronary plaque; RCA, right coronary artery; TCFA, thin-cap fibroatheroma.

Clinical Outcomes

Clinical outcomes after follow-up CCTA were obtained from medical records, and the association between each HRPF and clinical outcomes was evaluated. The primary outcome was defined as a composite of cardiac death, target lesion-related myocardial infarction, and target lesion-related revascularization, and individual outcomes were recorded as secondary outcomes.

Statistical Analysis

Categorical variables are presented as numbers and percentages, whereas continuous variables are presented as the mean±SD or the median with interquartile range (IQR) depending on their distribution. Student's t-test was used for comparisons of continuous variables that were normally distributed. The Wilcoxon test was used for comparisons of continuous variables that were not normally distributed. Categorical variables were examined by the Chi-squared test. Receiver operating characteristic (ROC) curve analysis was performed to determine the optimal cut off value of maximum lipid arc for the prediction of high-risk LRCP. All tests were 2-sided and P<0.05 was considered significant. Statistical analysis were conducted using JMP version 14 (SAS Institute, Cary, NC, USA).

Results

Patient Characteristics

Twenty-eight patients were included in this study. Among the 28 lesions with LRCs on baseline OCT, 19 (67.9%) were observed to have PR, 19 (67.9%) were observed to have vLAP, 6 (21.4%) were observed to have NRS, and 18 (64.3%) were observed to have spotty calcification on CCTA at the 10-month follow-up. High-risk LRCP was observed in 12 lesions (42.9%). Patient characteristics and laboratory findings are presented in **Table 1**. There were no significant differences between the low- and high-risk LRCP groups. Major coronary risk factors for advanced

arteriosclerosis, such as dyslipidemia and diabetes, were considered to be well treated in both groups.

Baseline OCT Findings and Follow-up CCTA Findings

Baseline OCT findings showed that patients with high-risk LRCP had a significantly larger maximum lipid arc than those with low-risk LRCP (221±62° vs. 179±44°, respectively; P=0.04; **Table 2**), but there were no significant differences in TCFA or macrophages between the 2 groups. The CCTA findings are presented in **Table 3**. Patients with high-risk LRCP had a significantly higher incidence of PR, vLAP, NRS, and spotty calcification. There were no differences in other CCTA findings between the 2 groups. The presence of implanted stents did not affect the CCTA analysis.

Patient Characteristics and Baseline OCT Findings for Each HRPF

Patients with PR were predominantly male. Lesions with PR had a significantly larger maximum lipid arc on baseline OCT but no significant difference in lipid index or TCFA compared with lesions without PR (**Supplementary Table 1**).

Patients with vLAP were significantly younger and had significantly higher triglycerides (TG) at follow-up than those without vLAP (**Supplementary Table 2**). There were no significant differences in characteristics and baseline OCT findings between patients with and without NRS (**Supplementary Table 3**). Ezetimibe was more commonly prescribed for patients with than without spotty calcification, and high-density lipoprotein cholesterol (HDL-C) levels were lower at follow-up in patients with spotty calcification (**Supplementary Table 4**).

Clinical Outcomes

The median follow-up duration after follow-up CCTA was 22 months (IQR 7–37 months). During follow-up after CCTA, the incidence of primary outcomes was significantly higher among patients with high-risk LRCP

Table 3. Follow-up Computed Tomography Angiography Findings in the Low- and High-Risk LRCP Groups			
	High-risk LRCP (n=12)	Low-risk LRCP (n=16)	P value
Follow-up duration (months)	10 [8–11]	9 [8–11]	0.92
Positive remodeling	12 (100)	7 (43.8)	<0.001
vLAP	11 (91.7)	8 (50.0)	0.01
Napkin-ring sign	6 (50)	0 (0)	<0.001
Spotty calcification	11 (91.7)	7 (43.8)	0.01
Large calcification	4 (33.3)	10 (62.5)	0.13
Plaque length (mm)	21.5±8.9	19.7±9.8	0.63
Total plaque volume (mm ³)	346 [215–592]	304 [188–517]	0.58
LAP volume (mm ³)	127 [103–202]	94 [61–170]	0.16
LAP volume/total plaque volume (%)	39.0±6.5	36.0±9.2	0.34
Maximum LAP area (mm ²)	8.7±2.7	7.5±3.0	0.28
Total plaque area (mm ²)	20.3±6.7	19.7±7.7	0.82
Maximum LAP area/total plaque area (%)	43.9±9.0	39.9±11.1	0.31
Area stenosis			0.78
Mild (1–39%)	7 (58.3)	8 (50.0)	
Moderate (40–69%)	3 (25.0)	6 (37.5)	
Severe (70–99%)	2 (16.7)	2 (12.5)	
Total occlusion	0 (0)	0 (0)	
Total no. HRPFs			
0	0 (0)	1 (6.3)	
1	0 (0)	8 (50.0)	
2	0 (0)	7 (43.8)	
3	8 (66.7)	0 (0)	
4	4 (33.3)	0 (0)	

Unless indicated otherwise, data are given as n (%), mean±SD, or median (interquartile range). HRPFs, high-risk plaque features; LAP, low attenuation plaque; LRCP, lipid-rich coronary plaque; vLAP, very low attenuation plaque.

Table 4. Clinical Outcomes			
	High-risk LRCP (n=12)	Low-risk LRCP (n=16)	P value
Primary outcome	4 (33.3)	0 (0)	0.01
Secondary outcomes			
Cardiac death	0 (0)	0 (0)	NA
Target lesion-related MI	1 (8.3)	0 (0)	0.24
Target lesion-related revascularization	4 (33.3)	0 (0)	0.01

Unless indicated otherwise, values are presented as n (%). The primary outcome is a composite of cardiac death, target lesion-related myocardial infarction (MI), and target lesion-related revascularization. LRCP, lipid-rich coronary plaque; NA, not assessed.

than among those with low-risk LRCP (33.0% vs. 0%, respectively; $P=0.01$; **Table 4**; **Figure 4**). The incidence of primary outcomes was also significantly higher among patients with spotty calcification than those without (**Supplementary Table 5**).

Discriminator of High-Risk LRCP on 10-Month Follow-up CCTA

Based on ROC curve analysis of the association between maximum lipid arc and LRCP, the optimal cut-off value for predicting high-risk LRCP on CCTA was a maximum lipid arc $>154^\circ$. The accuracy of this cut-off was 64.3%, with sensitivity, specificity, positive predictive and negative predictive values of 100%, 37.5%, 54.5%, and 100%, respectively.

Discussion

Recent studies have shown the efficacy of OMT alongside blood pressure control, intensive lipid-lowering therapy, and diabetes control for advanced coronary artery disease.^{1,2} However, 27% of patients with OMT died or experienced ACS during a median follow-up of 4.6 years.¹ Previous invasive imaging studies showed that the presence of LRCP was a precursor of future coronary events.^{10–13} Thus, detecting high-risk LRCPs that remain unstable after OMT is essential to prevent future cardiac events. The aim of this study was to show the relationship between LRCP on baseline OCT and HRPF at follow-up CCTA after OMT. The main findings of this study are that: (1) 42.9% of OCT-detected LRCP remained vulnerable at the 10-month follow-up CCTA; (2) lesions with high-risk

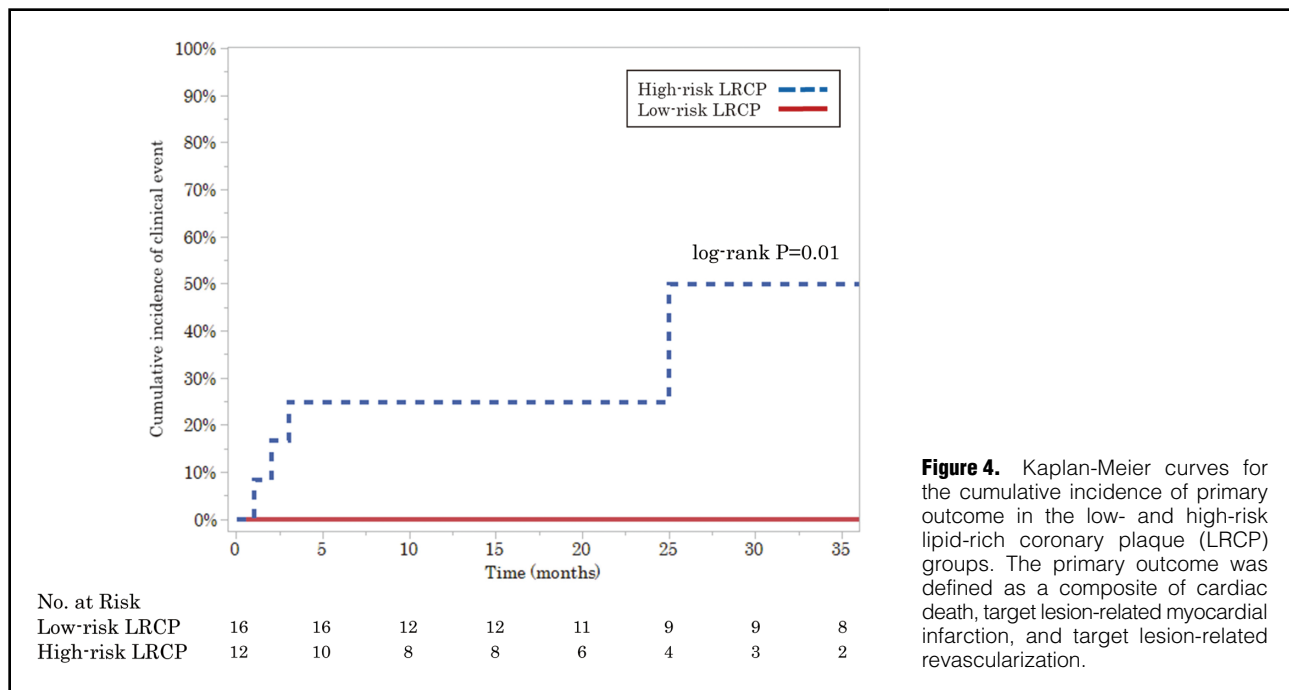


Figure 4. Kaplan-Meier curves for the cumulative incidence of primary outcome in the low- and high-risk lipid-rich coronary plaque (LRCP) groups. The primary outcome was defined as a composite of cardiac death, target lesion-related myocardial infarction, and target lesion-related revascularization.

LRCP at follow-up had a larger maximum lipid arc on baseline OCT; (3) patients with high-risk LRCP had worse clinical outcomes; and (4) spotty calcification at follow-up CCTA was associated with the primary outcome.

LRCP and Plaque Vulnerability After OMT

Several studies reported that TCFA, LRCP, and microchannels in non-culprit lesions on OCT were predictors of subsequent target lesion progression and ACS.^{10–14,24} The cumulative risk of ACS was estimated to be approximately 10-fold higher in patients with than without LRCP or TCFA in non-culprit lesions.¹⁰ In addition, patients with LRCP in non-culprit lesions had double the incidence of non-culprit lesion-related cardiac events.^{12,13} However, those studies did not detail the medication at follow-up or how risk factors were controlled. The patients in the present study underwent OMT following current guidelines for advanced atherosclerosis and showed well-controlled lipid and diabetic profiles at follow-up. However, 42.9% of patients with OCT-detected LRCP remained unstable at the 10-month follow-up CCTA. A study investigating non-culprit coronary plaques with virtual histology–IVUS reported that 65% of TCFA changed to thick fibroatheroma, but more than 90% of fibroatheromas stayed fibroatheromas after 1 year of follow-up.²⁵ These findings suggest that lesions with a lipid or necrotic core in the non-culprit artery still have a lipid or necrotic core at the 1-year follow-up. Therefore, the sustained plaque vulnerability of LRCP may be still left even after OMT.

This study showed that the maximum lipid arc was correlated with high-risk LRCP on follow-up CCTA. However, we could not find a relationship between high-risk LRCP and the lipid index, which is correlated with lipid volume. When lipid length increases, the lipid area in a cross-section becomes smaller and vice versa. It has been reported that a larger OCT-derived lipid arc was significantly correlated with a greater remodeling index.²⁶ A

larger remodeling index indicates the presence of a large lipid core and PR, and PR is also one of the features of vulnerable plaque.¹⁵ Thus, large lipid arc in cross-section become vulnerable LRCPs even after OMT. Based on ROC curve analysis, the optimal cut-off to predict high-risk LRCP on 10-month follow-up CCTA was a maximum lipid arc of 154°. An OCT study reported a maximum lipid arc $\geq 185^\circ$ at the non-culprit lesion as a good predictor of ACS.¹⁰ A larger maximum lipid arc at the non-culprit lesion is thought to be a sensitive discriminator for both high-risk LRCP on follow-up CCTA and future ACS. The CCTA findings in this study showed a larger LAP volume suggestive of the presence of a large lipid core in patients with high-risk LRCP.

We could not find a relationship between high-risk LRCP and TCFA, probably because the patients in our study underwent intensive lipid-lowering statin therapy. Previous studies have confirmed the increase in fibrous cap thickness with intensive statin therapy.^{27,28} A thin fibrous cap may be modified by further intensive statin therapy. Although TCFA detected by baseline OCT is associated with future cardiovascular events, TCFA stabilizing into low-risk LRCP by OMT must be low risk for future cardiovascular events. Conversely, despite intensive statin therapy, it is not easy to decrease a larger lipid volume. Thus, only the maximum lipid arc is a discriminator of high-risk LRCP on CCTA.

LDL-C and LRCP

The mean LDL-C at follow-up was 67 mg/dL in patients with high-risk LRCP. This suggests that LDL-C < 70 mg/dL may not effectively reduce lipid volume in patients with a large LRCP. Although the PRECISE-IVUS study indicated that percentage plaque volume regressed in ACS patients with LDL-C < 80 mg/dL after 1-year of lipid-lowering therapy, the study did not show the presence of LRCP or fibroatheromas.²⁹ A CCTA study reported that the

remodeling index and minimum CT value improved in patients whose LDL-C was controlled around 19 mg/dL after 6 months of lipid-lowering therapy; these findings were not observed in patients whose LDL-C was controlled to 69 mg/dL.³⁰ Therefore, to reduce lipid volume in patients with large LRCP, the target LDL-C must be as low as possible. Patients with a larger lipid arc at the non-culprit lesion on baseline OCT, especially an arc >154°, must be treated with aggressive lipid-lowering therapy.

High-Risk LRCP and Clinical Outcomes

In previous reports, HRPf on CCTA, such as PR, vLAP, NRS, and spotty calcification, were independent predictors of future cardiac events.^{15,17} During a mean follow-up of 27 months, 22.2% of patients with both PR and vLAP, and 3.7% of patients with either PR or vLAP, developed ACS.¹⁵ Over 10 years of follow-up, major adverse cardiovascular events occurred in approximately 8% of patients with spotty calcification.¹⁷ Although in the present study patients with low-risk LRCP on follow-up CCTA had no clinical events, the primary outcome was documented in 33.3% of patients in the high-risk LRCP group during follow-up after CCTA. Thus, high-risk LRCP is believed to be a greater risk factor for future cardiac events. Notably, patients with low-risk LRCP undergoing OMT rarely had future cardiac events.

The cardiac event rate related to LRCP detected by IVUS or OCT at the non-culprit lesion was approximately 10% over a 3- or 4-year follow-up;^{11,12} the incidence of cardiac events in the present study was markedly higher. Because the presence of large lipids was demonstrated in high-risk LRCP on baseline OCT and follow-up CCTA after OMT, it is important to prevent further progression of vulnerable plaques or future cardiac events. As mentioned above, aggressive lipid-lowering therapy can reduce plaque volume.²⁸ The present study demonstrated an association between spotty calcification and the primary outcome. This finding is consistent with previous studies showing that the presence of spotty calcification results in the onset of ACS.¹⁵ Although plaque volume may be controlled by aggressive medical therapy, there is no way of reversing spotty calcification. A lesion with a large lipid core and spotty calcification warrants prompt, robust medication.

Study Limitations

This study has several limitations. First, the study population was very small because only patients who underwent both baselines OCT and follow-up CCTA were included. At Nara Medical University, myocardial scintigraphy is often performed in order to follow coronary artery disease patients after PCI. However, myocardial scintigraphy cannot access plaque morphology. Routine coronary angiography is not recommended for asymptomatic coronary artery disease patients without ischemia after PCI.³¹ Therefore, we sometimes performed follow-up CCTA to check restenosis and the change in plaque morphology in high-risk patients. Second, it is generally difficult to assess plaques with large calcification on CCTA. However, because this study focused on LRCP, lesions with large calcification were rare. Third, this study had biases, such as selection and confounding bias, because it was a retrospective single-center study. Hence, further larger population studies are needed, and we believe our study becomes a pilot study of the fate of LRCP.

Conclusions

High-risk LRCP at follow-up CCTA was correlated with a larger maximum lipid arc on baseline OCT. Our results suggest that aggressive treatment for patients with large LRCP may reduce vulnerable coronary plaque features and prevent future cardiac events.

Acknowledgments

The authors thank the patients, participating cardiologists, and staff who contributed to this study.

Sources of Funding

This study did not receive any specific funding.

Disclosures

None declared.

IRB Information

This study was approved by the Ethics Committee of Nara Medical University (ID #1759-2).

Data Availability

The deidentified participant data will not be shared.

References

1. Boden WE, O'Rourke RA, Teo KK, Hartigan PM, Maron DJ, Kostuk WJ, et al. Optimal medical therapy with or without PCI for stable coronary disease. *N Engl J Med* 2007; **356**: 1503–1516.
2. Maron DJ, Hochman JS, Reynolds HR, Bangalore S, O'Brien SM, Boden WE, et al. Initial invasive or conservative strategy for stable coronary disease. *N Engl J Med* 2020; **382**: 1395–1407.
3. Kimura K, Kimura T, Ishihara M, Nakagawa Y, Nakao K, Miyauchi K, et al. JCS 2018 guideline on diagnosis and treatment of acute coronary syndrome. *Circ J* 2019; **83**: 1085–1196.
4. Collet JP, Thiele H, Barbato E, Barthélémy O, Bauersachs J, Bhatt DL, et al. 2020 ESC guidelines for the management of acute coronary syndromes in patients presenting without persistent ST-segment elevation. *Eur Heart J* 2021; **42**: 1289–1367.
5. Taguchi I, Imuro S, Iwata H, Takashima H, Abe M, Amiya E, et al. High-dose versus low-dose pitavastatin in Japanese patients with stable coronary artery disease (REAL-CAD): A randomized superiority trial. *Circulation* 2018; **137**: 1997–2009.
6. Sabatine MS, Giugliano RP, Keech AC, Honarpour N, Wiviott SD, Murphy SA, et al. Evolocumab and clinical outcomes in patients with cardiovascular disease. *N Engl J Med* 2017; **376**: 1713–1722.
7. Bona KH, Mannsverk J, Wiseth R, Aaberge L, Myreng Y, Nygård O, et al. Drug-eluting or bare-metal stents for coronary artery disease. *N Engl J Med* 2016; **375**: 1242–1252.
8. Palmerini T, Benedetto U, Biondi-Zoccai G, Della Riva D, Bacchi-Reggiani L, Smits PC, et al. Long-term safety of drug-eluting and bare-metal stents: Evidence from a comprehensive network meta-analysis. *J Am Coll Cardiol* 2015; **65**: 2496–2507.
9. Cheng JM, Garcia-Garcia HM, de Boer SP, Kardys I, Heo JH, Akkerhuis KM, et al. In vivo detection of high-risk coronary plaques by radiofrequency intravascular ultrasound and cardiovascular outcome: Results of the ATHEROREMO-IVUS study. *Eur Heart J* 2014; **35**: 639–647.
10. Kubo T, Ino Y, Mintz GS, Shiono Y, Shimamura K, Takahata M, et al. Optical coherence tomography detection of vulnerable plaques at high risk of developing acute coronary syndrome. *Eur Heart J Cardiovasc Imaging*, doi:10.1093/ehjci/jeab028.
11. Stone GW, Maehara A, Lansky AJ, de Bruyne B, Cristea E, Mintz GS, et al. A prospective natural-history study of coronary atherosclerosis. *N Engl J Med* 2011; **364**: 226–235.
12. Xing L, Higuma T, Wang Z, Aguirre AD, Mizuno K, Takano M, et al. Clinical significance of lipid-rich plaque detected by optical coherence tomography: A 4-year follow-up study. *J Am Coll Cardiol* 2017; **69**: 2502–2513.
13. Prati F, Romagnoli E, Gatto L, La Manna A, Burzotta F, Ozaki Y, et al. Relationship between coronary plaque morphology of the left anterior descending artery and 12 months clinical outcome:

- The CLIMA study. *Eur Heart J* 2020; **41**: 383–391.
14. Uemura S, Ishigami K, Soeda T, Okayama S, Sung JH, Nakagawa H, et al. Thin-cap fibroatheroma and microchannel findings in optical coherence tomography correlate with subsequent progression of coronary atheromatous plaques. *Eur Heart J* 2012; **33**: 78–85.
 15. Motoyama S, Sarai M, Harigaya H, Anno H, Inoue K, Hara T, et al. Computed tomographic angiography characteristics of atherosclerotic plaques subsequently resulting in acute coronary syndrome. *J Am Coll Cardiol* 2009; **30**: 49–57.
 16. Motoyama S, Ito H, Sarai M, Kondo T, Kawai H, Nagahara Y, et al. Plaque characterization by coronary computed tomography angiography and the likelihood of acute coronary events in mid-term follow-up. *J Am Coll Cardiol* 2015; **66**: 337–346.
 17. Finck T, Stojanovic A, Will A, Hendrich E, Martinoff S, Hausleiter J, et al. Long-term prognostic value of morphological plaque features on coronary computed tomography angiography. *Eur Heart J Cardiovasc Imaging* 2020; **21**: 237–248.
 18. Andreini D, Magnoni M, Conte E, Masson S, Mushtaq S, Berti S, et al. Coronary plaque features on CTA can identify patients at increased risk of cardiovascular events. *JACC Cardiovasc Imaging* 2020; **13**: 1704–1717.
 19. Lee SE, Sung JM, Andreini D, Al-Mallah MH, Budoff MJ, Cademartiri F, et al. Differences in progression to obstructive lesions per high-risk plaque features and plaque volumes with CCTA. *JACC Cardiovasc Imaging* 2020; **13**: 1409–1417.
 20. Tearney GJ, Regar E, Akasaka T, Adriaenssens T, Barlis P, Bezerra HG, et al. Consensus standards for acquisition, measurement, and reporting of intravascular optical coherence tomography studies: A report from the International Working Group for Intravascular Optical Coherence Tomography Standardization and Validation. *J Am Coll Cardiol* 2012; **59**: 1058–1072.
 21. Russo M, Kim HO, Kurihara O, Araki M, Shinohara H, Thondapu V, et al. Characteristics of non-culprit plaques in acute coronary syndrome patients with layered culprit plaque. *Eur Heart J Cardiovasc Imaging* 2020; **21**: 1421–1430.
 22. Soeda T, Uemura S, Okayama S, Kawakami R, Sugawara Y, Nakagawa H, et al. Intensive lipid-lowering therapy with rosuvastatin stabilizes lipid-rich coronary plaques: Evaluation using dual-source computed tomography. *Circ J* 2011; **75**: 2621–2627.
 23. Lee JM, Choi KH, Koo BK, Park J, Kim J, Hwang D, et al. Prognostic implications of plaque characteristics and stenosis severity in patients with coronary artery disease. *J Am Coll Cardiol* 2019; **73**: 2413–2424.
 24. Iannaccone M, Quadri G, Taha S, D'Ascenzo F, Montefusco A, Omede' P, et al. Prevalence and predictors of culprit plaque rupture at OCT in patients with coronary artery disease: A meta-analysis. *Eur Heart J Cardiovasc Imaging* 2016; **17**: 1128–1137.
 25. Kubo T, Maehara A, Mintz GS, Doi H, Tsujita K, Choi SY, et al. The dynamic nature of coronary artery lesion morphology assessed by serial virtual histology intravascular ultrasound tissue characterization. *J Am Coll Cardiol* 2010; **55**: 1590–1597.
 26. Raffel OC, Merchant FM, Tearney GJ, Chia S, Gauthier DD, Pomerantsev E, et al. In vivo association between positive coronary artery remodelling and coronary plaque characteristics assessed by intravascular optical coherence tomography. *Eur Heart J* 2008; **29**: 1721–1728.
 27. Komukai K, Kubo T, Kitabata H, Matsuo Y, Ozaki Y, Takarada S, et al. Effect of atorvastatin therapy on fibrous cap thickness in coronary atherosclerotic plaque as assessed by optical coherence tomography: The EASY-FIT study. *J Am Coll Cardiol* 2014; **64**: 2207–2217.
 28. Hou J, Xing L, Jia H, Vergallo R, Soeda T, Minami Y, et al. Comparison of intensive versus moderate lipid-lowering therapy on fibrous cap and atheroma volume of coronary lipid-rich plaque using serial optical coherence tomography and intravascular ultrasound imaging. *Am J Cardiol* 2016; **117**: 800–806.
 29. Tsujita K, Sugiyama S, Sumida H, Shimomura H, Yamashita T, Yamanaga K, et al. Impact of dual lipid-lowering strategy with ezetimibe and atorvastatin on coronary plaque regression in patients with percutaneous coronary intervention: The multicentre randomized controlled PRECISE-IVUS trial. *J Am Coll Cardiol* 2015; **66**: 495–507.
 30. Hirai K, Imamura S, Hirai A, Ookawara S, Morishita Y. Effect of evolocumab on vulnerable coronary plaques: A serial coronary computed tomography angiography study. *J Clin Med* 2020; **9**: 3338.
 31. Yamagishi M, Tamaki N, Akasaka T, Ikeda T, Ueshima K, Uemura S, et al. JCS 2018 guideline on diagnosis of chronic coronary heart diseases. *Circ J* 2021; **85**: 402–572.

Supplementary Files

Please find supplementary file(s);
<http://dx.doi.org/10.1253/circrep.CR-21-0147>